

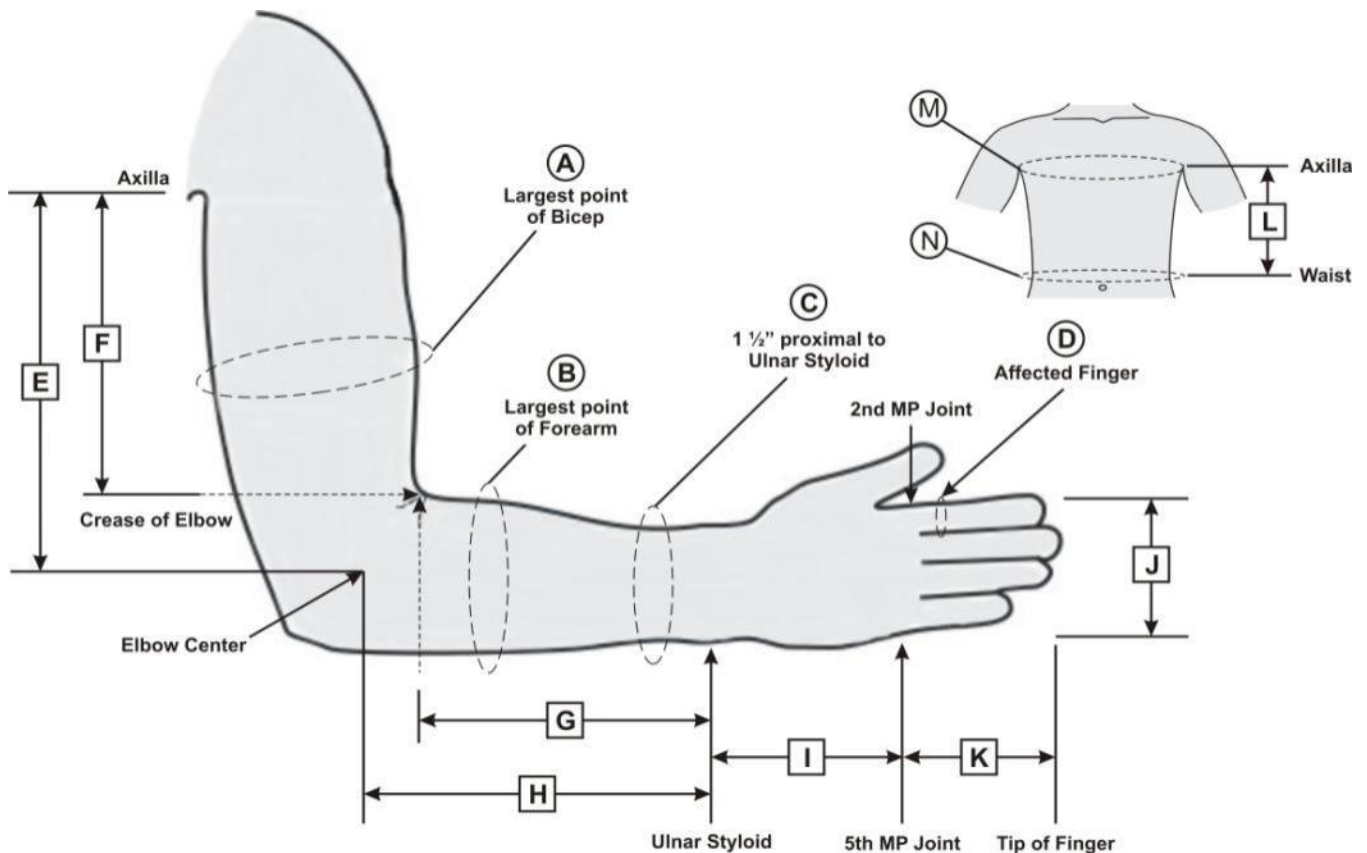
# MEASUREMENT GUIDE



# UPPER EXTREMITY

## Upper Extremity Measurement Chart

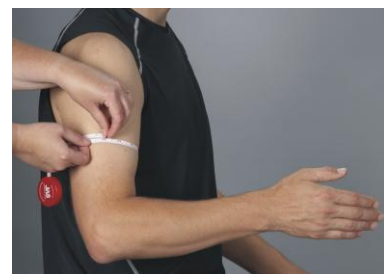A	Circumference: Largest point of Bicep
B	Circumference: Largest point of Forearm
C	Circumference: 1 1/2" (3.8 cm) proximal to Ulnar Styloid
D	Circumference: Affected Finger proximal Phalanx
E	Length: Axilla to Medial Epicondyle
F	Length: Axilla to Crease of Elbow
G	Length: Crease of Elbow to Ulnar Styloid
H	Length: Lateral Epicondyle to Ulnar Styloid
I	Length: Ulnar Styloid to 5 <sup>th</sup> MP Joint
J	Length: Width of Hand across MP Joints
K	Length: Affected Finger MP Joint to tip of Finger
L	Length: Axilla to Waist
M	Circumference: Chest at Axilla
N	Circumference: Waist at Belly Button



# UPPER EXTREMITY

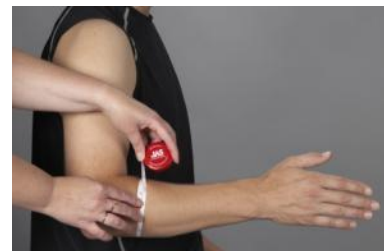## **A: Circumference at Largest Point on Bicep**

Measure patient at approximately the midpoint of the upper arm. Pull tape measure snug against the arm.



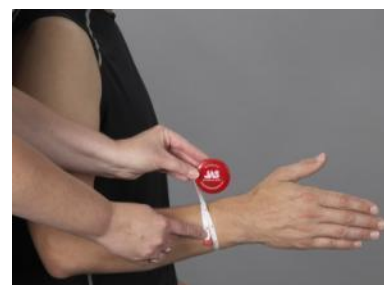## **B: Circumference at Largest Point on Forearm**

Measure patient at approximately 1 ½" below the crease of elbow. Pull tape measure snug against the arm.



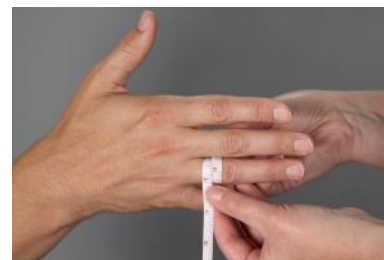## **C: Circumference 1 ½" proximal to Ulnar Styloid**

Measure patient at approximately 1 ½" above the Ulnar Styloid. Pull tape measure snug against the arm, so it does not indent the arm.



## **D: Circumference of Affected Finger proximal Phalanx**

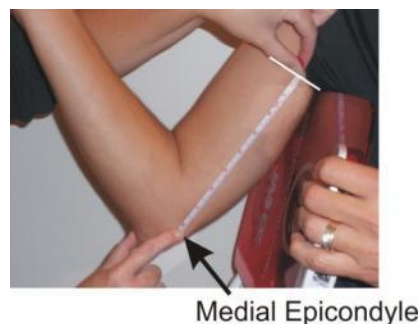Measure patient at approximately the midpoint of the proximal phalanx of the Affected Finger. Pull tape measure snug against the finger, so it does not indent the finger.



## **E: Length from Axilla to Medial Epicondyle**

Measurement from the location where the Proximal Bicep meets the Chest Pectoral Muscle to the Medial Epicondyle of the elbow. Pull tape measure so it is relatively straight.

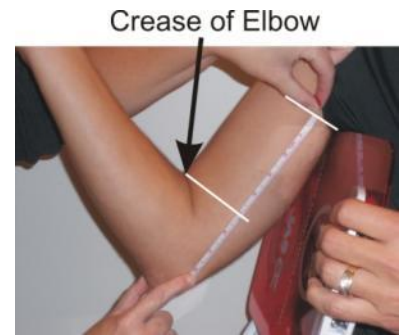Another option is to place a clip board, note pad, etc. under the patient's arm pit and measure the patient from the top of the clip board, etc. to Medial Epicondyle of the elbow. Pull tape measure so it is relatively straight.



# UPPER EXTREMITY

## F: Length from Axilla to Crease of Elbow

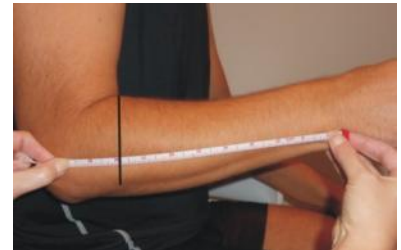
Measurement from the location where the Proximal Bicep meets the Chest Pectoral Muscle to the Medial Epicondyle of the elbow. Pull tape measure so it is relatively straight along the length of the upper arm, then eye-ball from the crease perpendicular to the tape measure to get the measurement. **(Do not measure at an angle!)**



Another option is place a clip board, note pad, etc. under the patient's arm pit and measure the patient from the top of the clip board, etc. to crease of elbow, also known as the bicipital mark. This is where the forearm meets the bicep when the arm is bent. Pull tape measure so it is relatively straight along the length of the upper arm, then eye-ball from the crease perpendicular to the tape measure to get the measurement. **(Do not measure at an angle!)**

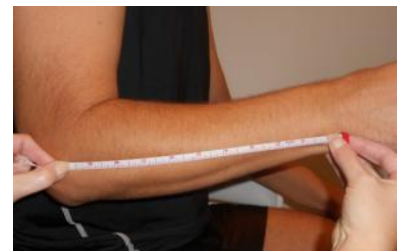## G: Length from Crease of Elbow to Ulnar Styloid

Measure patient from crease of elbow, also known as the bicipital mark, to Ulnar Styloid. The bicipital mark is where the forearm meets the bicep when the arm is bent. Pull tape measure so it is relatively straight along the length of the forearm arm, then eye-ball from the crease perpendicular to the tape measure to get the measurement. *(Do not measure from the crease to the Ulnar Styloid at an angle!)*



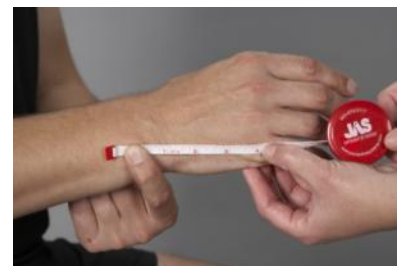## H: Length from Lateral Epicondyle to Ulnar Styloid

Measure patient from Lateral Epicondyle of elbow to Ulnar Styloid. Pull tape measure so it is relatively straight along the length of the forearm arm.



## I: Length from Ulnar Styloid to 5<sup>th</sup> MP joint

Measure patient from Ulnar Styloid to 5th MP Joint, knuckle at base of pinky finger. Pull tape measure so it is relatively straight along hand.



# UPPER EXTREMITY

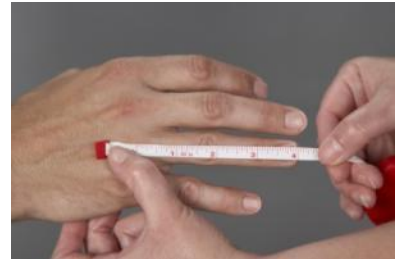## **J: Width of Hand across MP joints**

Measure patient across the MP joints (knuckles) from outside the 5th MP joint to outside the 2nd MP joint. Pull tape measure so it is relatively straight along hand.



## **K: Length of Affected Finger from MP Joint to tip of Finger**

Measure patient from MP Joint (knuckle) of Affected Finger to Tip of Affected Finger. Pull tape measure so it is relatively straight along finger.



## **L: Length from Axilla to Waist**

Measurement from the location where the Proximal Bicep meets the Chest Pectoral Muscle to Waist at approximately 1" above Belly Button. For the arm pit end, with the arm slightly abducted, measure where the bicep meets the body. Pull tape measure so it is relatively straight along the side of body.




## **M: Circumference of Chest at Axilla**

Measure patient around the Chest at the Axilla (arm pit), for women, the tape should go above the breast area. Pull tape measure so it is relatively snug and level around the chest.



## **N: Circumference of Waist at Belly Button**

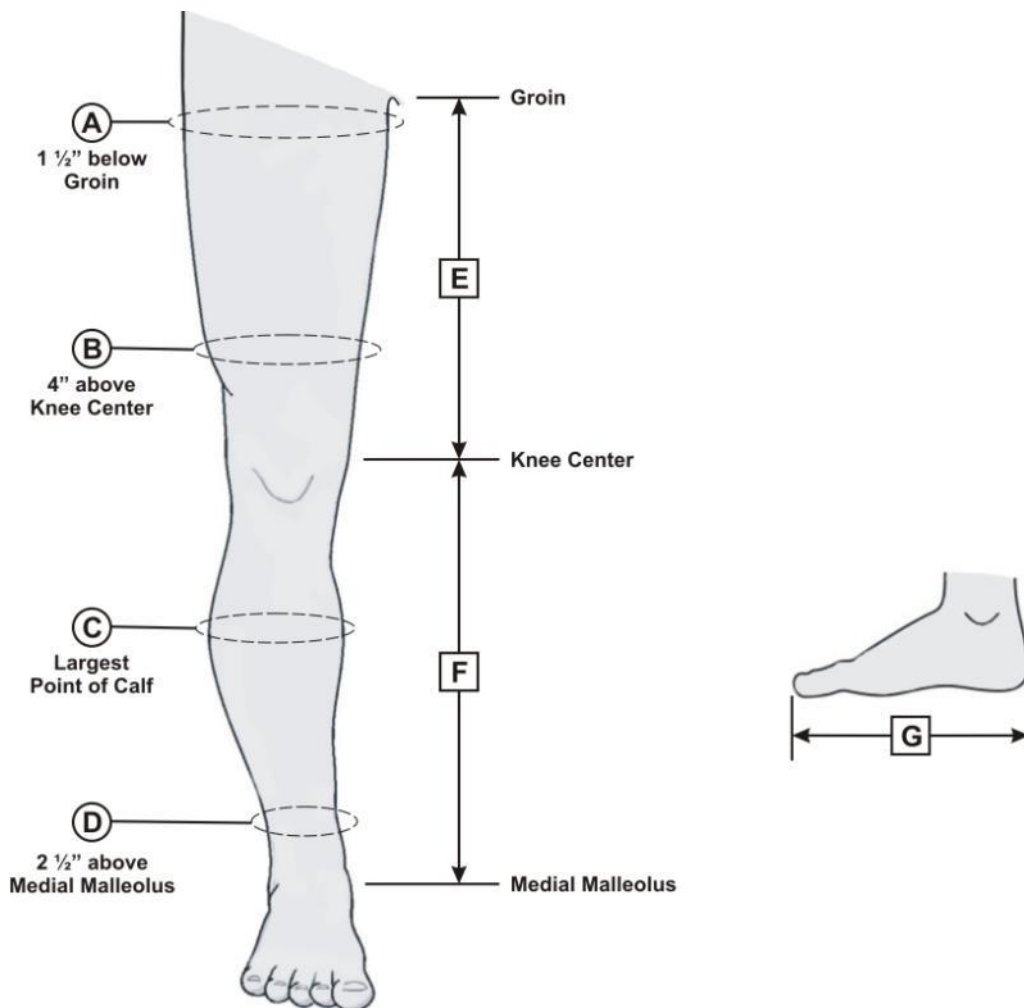
Measure patient around the Waist at the Belly Button. Pull tape measure so it is relatively snug and level around the Waist.



# LOWER EXTREMITY

## Lower Extremity Measurement Chart

- A Circumference: 1 1/2" (3.8 cm) below Groin
- B Circumference: 4" (10.2 cm) above Knee Center
- C Circumference: Largest point of Calf
- D Circumference: 2 1/2" (6.4 cm) above Medial Malleolus
- E Length: Groin to Knee Center (*not center of Knee Cap*)
- F Length: Knee Center (*not center of Knee Cap*) to Medial Malleolus
- G Length: Foot Length





# LOWER EXTREMITY

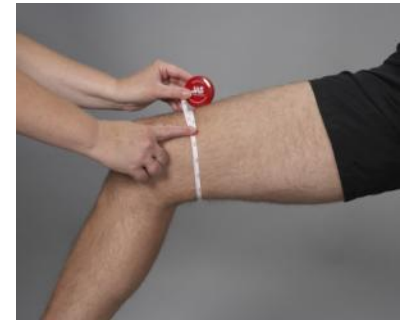## A: Circumference at 1 ½" below Groin

Measure patient at approximately 1 ½" below the Groin. Pull tape measure snug against the leg, so it does not indent the leg.



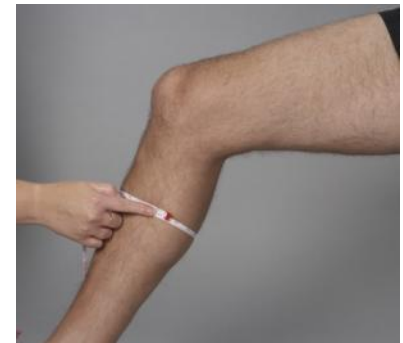## B: Circumference at 4" above Knee Center

Measure patient at approximately 4" above Knee Center. Knee Center can be approximated by locating the Medial Epicondyle of the Knee. Pull tape measure snug against the leg, so it does not indent the leg.



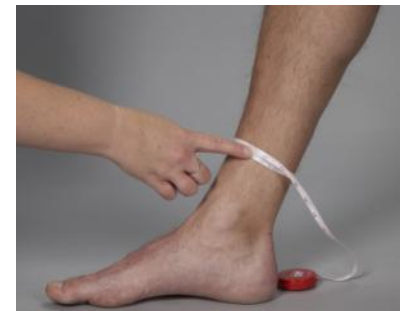## C: Circumference at Largest Point on Calf

Measure patient at largest circumference of the calf. Pull tape measure snug against the leg, so it does not indent the leg.



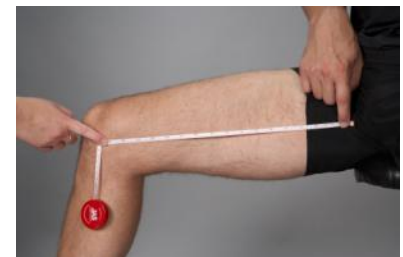## D: Circumference at 2 ½" above Medial Malleolus

Measure patient at 2 ½" above the Medial Malleolus. The Medial Malleolus is the bony bump on the inside of the ankle. Pull tape measure snug against the leg, so it does not indent the leg.



## E: Length from Groin to Knee Center

Measure patient from Groin to Knee Center. Have patient hold the tape measure at inside of leg comfortably up in the Groin, at the location that you would want the proximal end of the thigh cuff to end. *(Note: If there is excessive abdominal tissue on top of the thigh, start the end of the tape measure from that location along the inside of the thigh.)* Knee Center can be approximated by locating the Medial Epicondyle of the Knee. **(Do not measure to the center of the patella.)** Pull tape measure so it is straight along the inside of the leg.

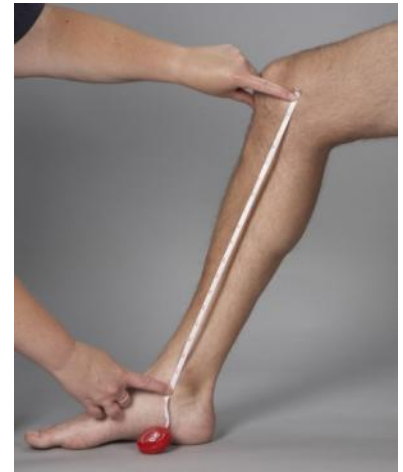


## LOWER EXTREMITY

---

### **F: Length from Knee Center to Medial Malleolus**

Measure patient from Knee Center to Medial Malleolus. Knee Center can be approximated by locating the Medial Epicondyle of the Knee. The Medial Malleolus is the bony bump on the inside of the Ankle. **(Do not measure to the center of the patella.)** Pull tape measure so it is straight along the inside of the leg.



### **G: Length of Foot**

Measure patient from back of Heel to tip of the longest toe. Pull tape measure so it is straight along the side of the Foot.

